

Original article:

Surgical Management of Diaphyseal Fractures of Both Bones Forearm in Adults by Limited Contact Dynamic Compression Plate: A Prospective Study

Dr. Akella Suryanarayana Rao

Associate Professor, Department of Orthopaedics, Chennai Medical College Hospital & Research Centre, Irungalur, Tiruchirappalli, Tamil Nadu, India.

Corresponding Author:

Dr. Akella Suryanarayana Rao, Associate Professor, Department of Orthopaedics, Chennai Medical College Hospital & Research Centre, Irungalur, Tiruchirappalli, Tamil Nadu, India.

Abstract:

Background: The incidence of forearm fractures are increasing faster than the predicted rate due to increase in population, increasing number of vehicles rapid industrialization, increased incidence of violence and various sports activities have contributed to the increased incidence of fracture shaft of both bones forearm.. Conservative treatment has resulted in malunion, non-union, synostosis and ultimately poor functional outcome. Hence perfect fracture reduction and rigid fixation is mandatory and achieved by plating. The aim of this study to evaluate the union rates and functional outcome of open reduction and internal fixation of fracture both bones forearm with LC-DCP.

Materials & Methods: Patients who are admitted in Department of Orthopaedics, Chennai Medical College Hospital & Research Centre, Irungalur, Tiruchirappalli, Tamil Nadu (India) taken for study after obtaining their consent.

Results: This study consists of 30 cases of fracture BBFA. All cases were openly reduced and internally fixed with 3.5 mm LCDCP. Age distribution ranged from 15- 55 years with fracture being most common in 3rd and 4th decade (Average 31).Side affected 20 (66.66%) right side and 10 patients (33.33%) left side. Results were evaluated by Andersons scoring system. Using this scoring system we had 25 (83.33%) patients with excellent results, 4 (13.33%) patients with satisfactory results and 1 (3.3%) with unsatisfactory result (radioulnar synostosis). Superficial infection 2 (6.66%) posterior interosseous nerve injury 3 (10%) and Radioulnar synostosis 1 (3.3%) were complications.

Conclusion: Until newer implants are devised and extensively assessed as the versatile LCDCP these should be used as the implant of choice for all closed displaced diaphyseal fractures of both bones in forearm.

Keywords: Limited Contact Dynamic Compression Plate, Forearm, Diaphyseal Fracture, Radial Bone, Ulnar Bone.

INTRODUCTION

Fractures of the both bones in forearm present unique management problems. In these particular diaphyseal fractures of both bones in forearm, perhaps more than any others, the combination of anatomical reduction and skeletal stability with mobility of the extremity is necessary to produce excellent functional results. Of

all diaphysial fractures, only the forearm requires anatomical reduction and stable internal fixation, in order to maintain full function of the hand.¹

The incidence of forearm fractures are increasing faster than the predicted rate due to increase in population, increasing number of vehicles, rapid industrialization, increased incidence of violence and

various sports activities have contributed to the increased incidence of fracture shaft of both bones forearm.

The reasons for higher rate of non-union and malunion as well as poor functional outcome, are due to complex anatomical structure with coordination between muscles, tendon, bones and joints which is responsible for the multifold functions of the arm and hand including pronation and supination where the radius rotates around the ulna.

The radial bow should be maintained for the good functional outcome. It is important to regain the length of the bones, good opposition and alignment without any malrotation. Conservative treatment has resulted in malunion, non-union, synostosis and ultimately poor functional outcome. Hence perfect fracture reduction and rigid fixation is mandatory and achieved by plating. With conventional plating, the screw acts as an anchor, with its axial force press the plate against bone, which produces large frictional force at the bone plate interface and this force has been shown to cause vascular disturbance, especially in the periosteum.

This observation has led to the development of limited contact dynamic compression plate. The term limited contact dynamic compression plate(LC-DCP) stands for a new approach to plate fixation, reduced trauma to the bone, preservation of blood supply, avoidance of stress raisers produced at implant removal and improved healing.²

MATERIALS& METHODS

This is a prospective time bound study includes treatment of 30 cases of fracture of both bones of forearm by open reduction and internal fixation with 3.5 mm LC-DCP.

Inclusion Criteria

- a) Those patients who are above 18 years and below 60years.
- b) Patients with closed diaphyseal fractures of both bones of forearm.
- c) Patients medically fit for surgery.

Exclusion Criteria

- a) Those patients who are below 18years and above 60years.
- b) Patients with severe osteoporosis.
- c) Open fractures.
- d) Segmental fracture of radius and ulna.

On admission of the patient, a careful history was elicited from the patient and/or attendants to reveal the mechanism of injury and the severity of trauma. The patients were then assessed clinically to evaluate their general condition and the local injury.

The patient was taken for surgery after routine investigations and after obtaining fitness towards surgery. The investigations are as follows: Hb%, Urine for sugar, FBS, Blood urea, Serum creatinine, ECG and chest x-ray.

Proximal radius was approached by Dorsal Thompson incision and Volar Henry approach was used for middle and distal radius. A narrow 3.5 mm LC-DCP was used and a minimum of 5 cortices were engaged with screw fixation in each fragment.

Operative Procedure

After anaesthesia, part was painted and draped. The radius was approached by Dorsal Thomson/ Volar Henry's approach. For proximal radius and mid shaft fractures, Dorsal Thomson approach was preferred. The critical step in the dorsal approach is to identify and preserve the posterior interosseous nerve. The nerve is protected in the mass of supinator when the muscle is detached from the bone and retracted as it mainly travels within the substance of the muscle.

For distal radius fractures, Volar Henry's approach was preferred. Henry's approach allows a wide exposure of the anterior surface of the radius and exposes the bone over its entire length, if this is required. The approach can be extended across the elbow and into the hand. Ulna was approached directly over the subcutaneous border.

After identifying the fracture ends, periosteum was elevated and fracture ends were cleaned. With the help of reduction clamps fracture was reduced and held in position. The plate was then applied after contouring, if required. For upper third radial fractures, the plate was fixed dorsally, for distal two thirds, the plate was fixed dorsolaterally and for distal radial fractures the plate was fixed on the volar aspect. In ulna fractures plate was applied over the posteromedial surface of ulna.³

Using the neutral drill guide, the first screw is applied to the fragment, which forms an obtuse angle with the fracture near the plate. The resulting space between the fracture plane and plate undersurface guides the opposite fragment towards the plate. The arrow of the neutral drill guide points towards the fractures. 2.5 mm drill bit is used for drilling a hole through both cortices and with depth gauge appropriate 3.5 mm screw length is determined, 3.5 mm drill tap used before screw insertion.³

After adaptation of the fragments, a screw hole for axial compression is drilled in the fragment, which forms an acute angle near the plate. Here the load guide is used with the arrow pointing towards the fracture line to be compressed.

At this position, a lag screw will be inserted for axial compression. The lag screw is applied by subsequently over drilling (3.5 mm) the near cortex to create a gliding hole. The lag screw and remaining screws are inserted.

The contour between the plate and the screw head of the eccentrically placed screw moves the screw head towards the center of the plate and thus moves the fragment into the same direction.

In case of porotic, comminuted and / or small bones, long screws and / or a longer plate were used. Once stable fixation is achieved and hemostasis secured meticulously, the wound is closed in layers over a suction drain and sterile dressing is applied.

Physiotherapy.⁴

A posterior plaster splint was applied for comfort for 2 to 3 days. Patient was encouraged to perform both active and active-assisted range of motion exercises of shoulder and hand.

Elbow range of motion, supination and pronation exercises were begun as soon as remission of pain and swelling of forearm permits, usually after 2 to 3 days. Because of rigidity of fixation, rapid return of motion was expected. These isotonic exercises are very much essential for the excellent outcome. Physiotherapy helps in fracture union, as there is increased blood supply and tethering of muscles to the bone and soft tissue contracture is avoided. Thus physiotherapy with rigid fixation gives excellent results.

Follow-up

All the patients were followed up as monthly intervals for first 3 months and evaluation was done based on "Anderson et al scoring system".⁵

RESULTS

The present study showed the average age of patients was 31 years and maximum number of patients occurred in 15-30 years of age group (table 1). Out of 30 patients, 20 (66.66%) with right forearm fracture and 10 (33.3%) patients with left forearm fracture (table 2). 27(90%) patients had sound union in less than 6 months, 3 (10%) patients had delayed union

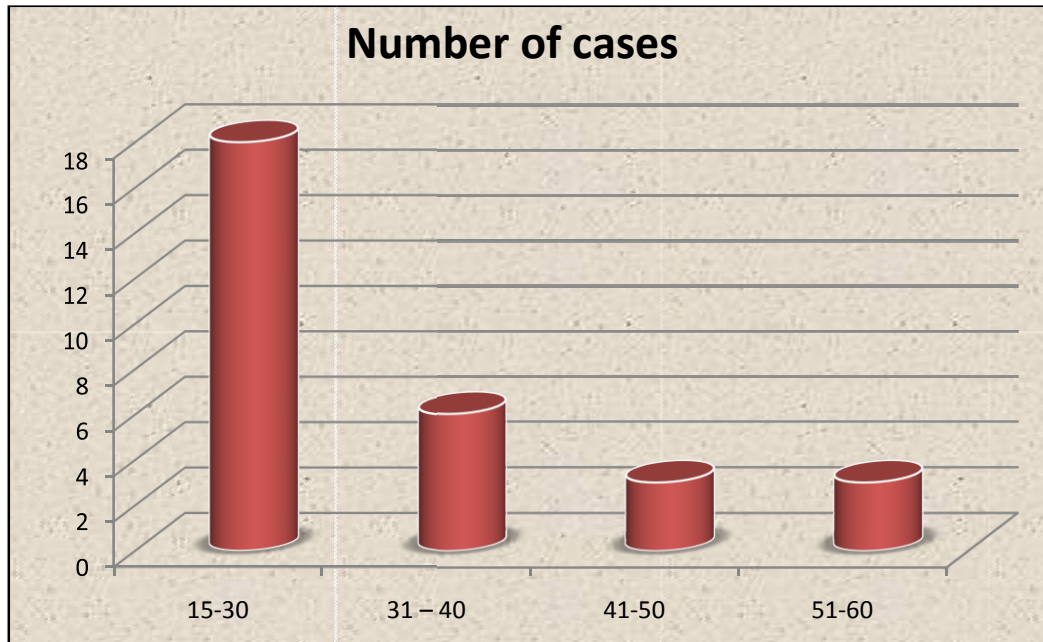
(table 3). Two patient developed superficial infection and three patient developed transient posterior interosseous nerve injury. Infection was controlled with appropriate antibiotics after culture and sensitivity report, Patients were treated with static cockup splint, which recovered in a span of about 6 weeks and One patients developed proximal

radio - ulnar synostosis and resulted in poor functional outcome. (Table 4)

Using the Anderson et al scoring system we had 25 (83.3%) patients with excellent results, 4 (13.3%) patients with satisfactory results and 1 (3.3%) patients with unsatisfactory result (radioulnar synostosis) (Table 5)

Table 1: Age wise distribution of cases

Age group (Years)	Number of cases	Percentage (%)
15-30	18	60%
31 – 40	6	20%
41-50	3	10%
51-60	3	10%
Total	30	100%



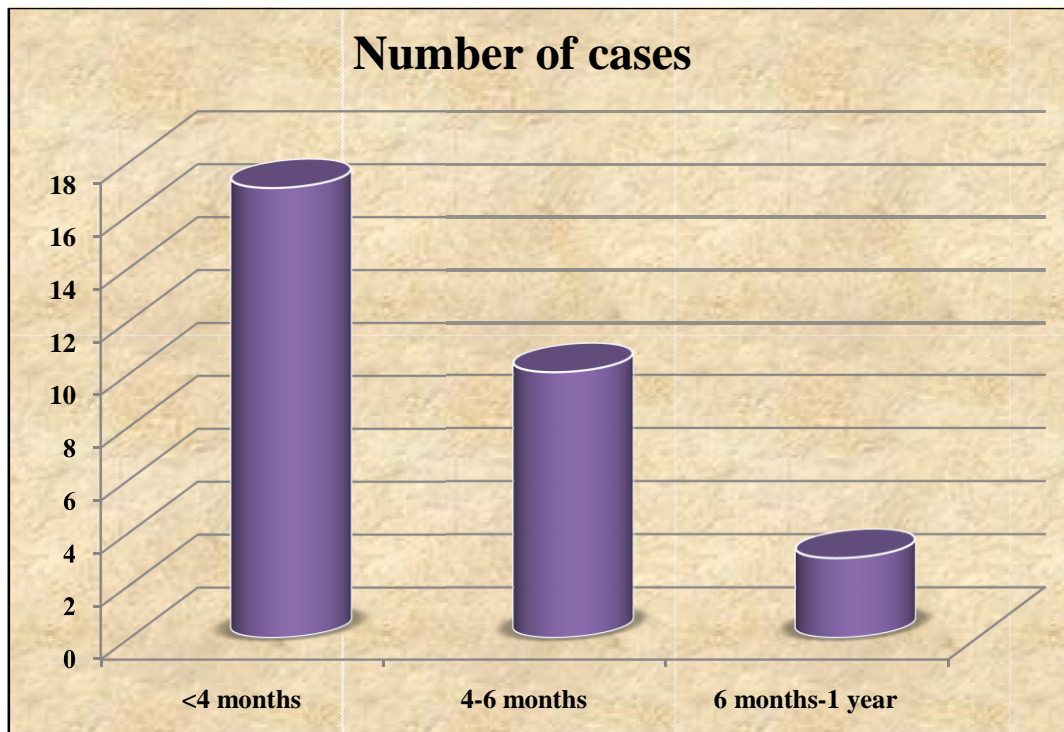
Graph 1: Age wise distribution of cases

Table 2: Side affected

Side affected	Number of cases	Percentage (%)
Right	20	66.66%
Left	10	33.33%
Total	30	100%

Table 3: Duration of fracture union

Duration of fracture union	Number of cases	Percentage (%)
<4 months	17	56.66%
4-6 months	10	33.33%
6 months-1 year	3	10%
Total	30	100%



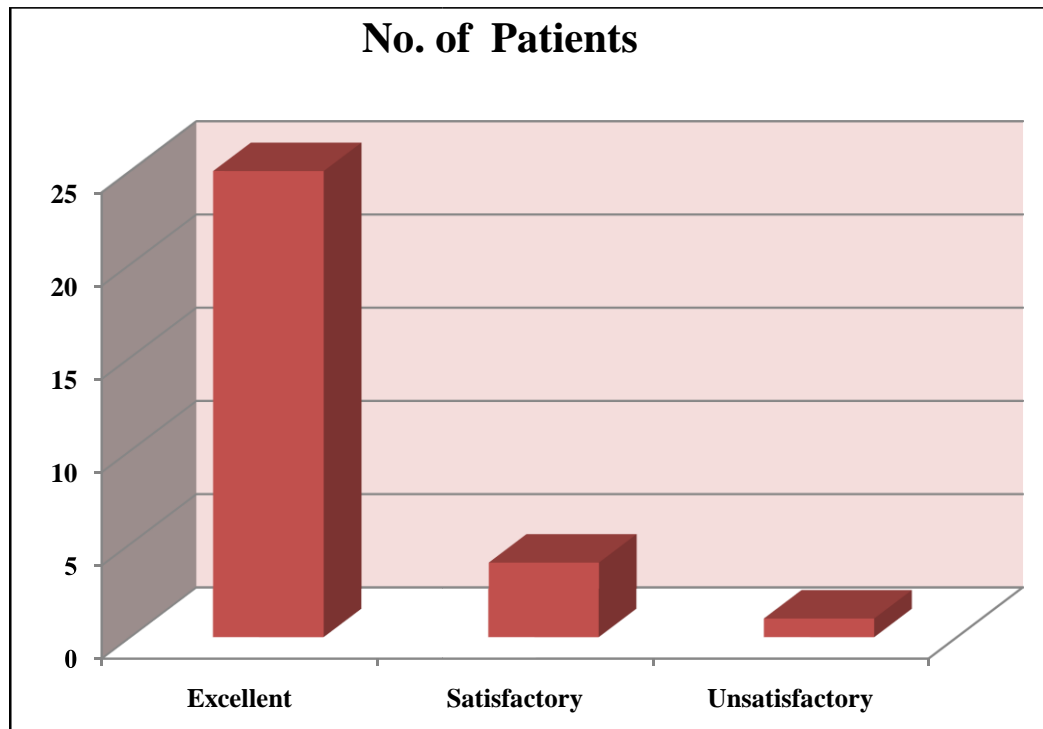
Graph 2: Duration of fracture union

Table 4: Complications

Complications	Number of cases	Percentage (%)
Superficial infection	2	6.66%
Posterior interosseous nerve injury	3	10%
Radioulnar stenosis	1	3.33%
Total	6	20%

Table 5: Functional Results

Results	No. of Patients	Percentage
Excellent	25	83.33%
Satisfactory	4	13.33%
Unsatisfactory	1	3.33%
Total	30	100%



Graph 3: Functional Results

DISCUSSION

Fracture both bones of forearm are commonly encountered in day-to-day orthopaedic practice in our hospital and it presents a formidable challenge to the orthopaedicians, as the various muscle forces acting

upon the fracture tend to displace it. Hence to provide the functional rehabilitation of the upper limb, anatomic reduction and rigid fixation is mandatory. As reported by Knight and Purvis closed reduction and its maintenance is difficult.⁶Intramedullary nails

have got high failure rate. Though there are few advantages like closed nailing, minimal tissue dissection and hospital stay. So, the best option is plating. Different types of plates are available. The dynamic compression plates (DCP) give good results, but there are few disadvantages. Since these plates interfere with periosteal circulation, osteoporosis and refracture are very common after plate removal. Much work had not been done on PC-fixators and as reported by Frankie Leung et al. they have no added advantage over the LC-DCP.⁷ So, the LC-DCP are the best implants for diaphyseal fracture of both bones forearm at present.

Age Distribution

Our findings are comparable to the study made by Chapman et al in 1989 witnessed 70% of patients between third and fourth decade and an average of 33 years.⁸

In 1964, Charnley series showed average age of 33 years (13-79).¹⁵ In 1972, Herbert S. Dodge and Gerald W. Cady found 24 years as the average age in their series.⁹ Berton R. Moed (1986) found the average age was 22 years.¹⁰ In 1992, Schemitsch, Emil H., found 24 years as average (16-83).¹¹ In 2003, Frankie Leung and Shew Ping chow accounted an average of 36 years (11-90 years).⁷ In the present study, fracture was common in third and fourth decade with average age of 31 years (15-55 years).

Extremity Affected

Burwell HN and Charnley AD reported about 50% incidence of fracture both bones in right forearm.¹² Chapman MW reported about 55% incidence of fractures of both bones in right extremity.⁸ We accounted about 66.66% incidence of fracture of both bones in right extremity, which is comparable to the previous studies.

Complications

In the present study, there was two case of superficial infection. It was treated with appropriate antibiotics and the wound healed without any problem. There were three cases of posterior interosseous nerve palsy. These cases were treated conservatively and there was spontaneous resolution of the nerve injury. We had a case of proximal radio-ulnar synostosis. We do not believe that this complication is related to the method of fixation, but rather to level of fracture and the degree of comminution. Chapman MW reported about 2.5% superficial infection, 1.5% posterior interosseous nerve palsy and 2.3% radio-ulnar synostosis⁸.

Anderson⁵ reported about 2.9% superficial infection, 2% posterior interosseous nerve palsy and 1.2% radio-ulnar synostosis. Frankie⁷ reported about 2% superficial infection and 3% posterior interosseous nerve palsy.

Time for Union

In most of the reported series, it is usually around 12 weeks except in the series of Anderson et al,⁵ where he reports a union time of 7.4 weeks (average). Time for union varies according to age, general condition, rigidity of fixation and presence of infection. Also inter observer variation is there, regarding time of union.

Absence of tenderness at the fracture site and disappearance of fracture line with callus formation is taken as union. Anderson's criteria for evaluation of union were taken into account. In our series, we had an average union time of 12.2 weeks, with the range of 9 to 28 weeks. We had 100% union of both radius and ulna.

Functional Results

Fracture union and range of movements are the two factors, which affect the functional outcome. So early

mobilization prevent soft tissue contracture, muscular tethering and improves the vascularity.

Anderson's et al scoring system was used as a measure for the functional outcome.⁵ Anderson et al reported about 54 (50.9%) cases as excellent, 37 (34.3%) satisfactory, 12 (11.3%) unsatisfactory and 2 (2.9%) as failure.⁵ Chapman et al reported about 36 (86%) cases as excellent, 3 (7%) satisfactory, 1 (2%) as unsatisfactory and 2 (5%) as failure.⁸ Frankie Leung reported 98% cases as excellent and 2% as satisfactory results.⁷ In present study, we had 25

(83.3%) with excellent results, 4 (13.3%) as satisfactory and 1 (3.3%) cases of unsatisfactory results.

CONCLUSION

LC-DCP facilitates biological, rigid fixation and early bone union with excellent radiological and functional outcome in majority of the patients.

Until newer implants are devised and extensively assessed as the versatile LCDCP these should be used as the implant of choice for all closed displaced diaphyseal fractures of both bones in forearm.

References:

1. Tile M. (1987) Fractures of the Radius and Ulna. In: The Rationale of Operative Fracture Care. Springer, Berlin, Heidelberg. 103-129.
2. Perrens M, Allgower M, Brunner H, Burch HB, Cordey J, Ganz R et al. The concept of biological plating using the limited contact dynamic compression plate (LC-DCP). *Injury* 1991; 22 (1): 1-41.
3. Perren SM: Basic Aspects of Internal Fixation. Chapter-1, in *Manual of Internal Fixation*, 3rd Edn., Allgower M., Schneider R, Willenegges, Berlin, Springer Verlag, 1991; 1.
4. Crenshaw, Andrew H. Fractures of shoulder girdle Arm and Forearm. Chapter-49, in *Campbell's Operative Orthopaedics*, Edt. Canale, S.Tery, St.Louis, Mosby, 1998; 2336-2353.
5. Anderson LD, Sisk TD, Tooms RE, Park W, I III. Compression: Plate fixation in acute diaphyseal fractures of radius and ulna. *JBJS* 1975; 57-A: 287-297.
6. Knight RA, Purvis GD. Fractures of both bones of the forearm in adults. *JBJS* 1949; 31-A: 755-764.
7. Leung, Frankie, Shew-Ping Chow. A prospective, randomized trial comparing the LC-DCP with the point contact fixator for forearm fractures. *JBJS* 2003; 85A (12): 2343-2348.
8. Chapman, Michael W, Gordon JE, Zissimos BS, Anthony G et al. Compression plate fixation of acute fractures of the diaphyses of radius and ulna. *JBJS* 1989; 71-A (2): 159-169.
9. Dodge, Herbert S., Gerald W. Cady: Treatment of fractures of the radius and ulna with compression plates. *JBJS* 1972; 54-A (6): 1167-1176.
10. Moed, Berton R, Kellam James F, Foster Robert J, Tilemaa. Immediate internal fixation of open fractures of the diaphysis of forearm. *JBJS* 1986; 68 (7): 1008-1016.
11. Schemitsch, Emil H, Robin R. Richards. The effect of malunion on functional outcome after plate fixation of fractures of both bones of forearm in adults. *JBJS* 1992; 74-A (7): 1068-1078.
12. Burwell HN, Arnold D. Charnley. Treatment of forearm fractures in adults with particular reference to plate fixation. *JBJS* 1964; 46-B (3), 404-424.